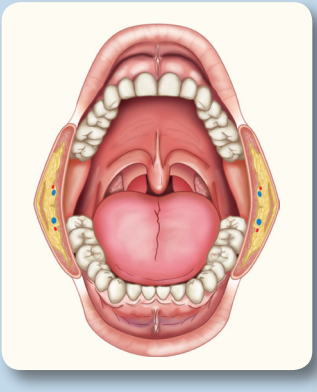

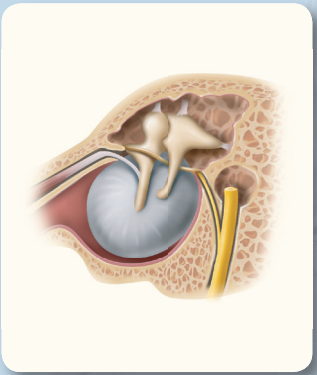

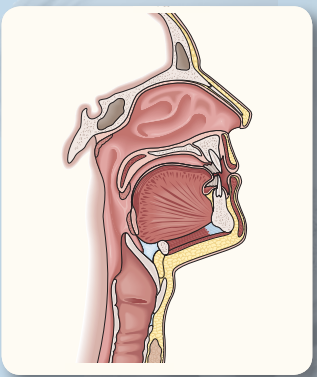

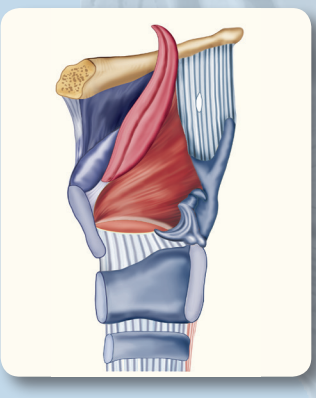

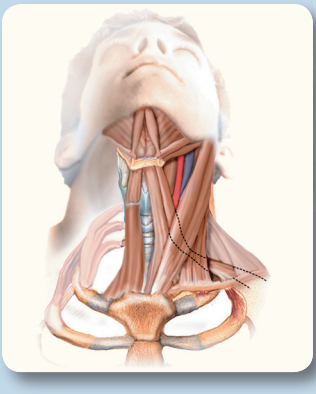

Anatomy & Physiology

for Speech, Language, and Hearing

SIXTH EDITION

J. Anthony Seikel
David G. Drumright
Daniel J. Hudock

Plural Publishing Inc.

Plural+PLUS
Companion Website

Anatomy & Physiology

for Speech, Language, and Hearing

SIXTH EDITION

Anatomy & Physiology

for Speech, Language, and Hearing

SIXTH EDITION

J. Anthony Seikel, PhD
David G. Drumright, BS
Daniel J. Hudock, PhD, CCC-SLP

Plural Publishing Inc.

PLURAL PUBLISHING
INC.

5521 Ruffin Road
San Diego, CA 92123

e-mail: information@pluralpublishing.com
Website: https://www.pluralpublishing.com

Typeset in 12/14 Adobe Garamond Pro by Flanagan's Publishing Services, Inc.
Printed in Canada by Friesens Corporation

Photography by Sarah Moore, Susan Duncan, Eric Gordon, and Brian Smith.

Library of Congress Cataloging-in-Publication Data:

Names: Seikel, John A., author. | Drumright, David G., author. | Hudock, Daniel J., author.
Title: Anatomy & physiology for speech, language, and hearing / J. Anthony Seikel, David G. Drumright, Daniel J. Hudock.
Other titles: Anatomy and physiology for speech, language, and hearing
Description: Sixth edition. | San Diego, CA : Plural Publishing, [2020] | Includes bibliographical references and index.
Identifiers: LCCN 2019029690 | ISBN 9781635502794 (hardcover) | ISBN 1635502799 (hardcover) | ISBN 9781635503005 (ebook)
Subjects: MESH: Speech—physiology | Language | Hearing—physiology | Nervous System—anatomy & histology | Respiratory System—anatomy & histology | Respiratory Physiological Phenomena
Classification: LCC QP306 | NLM WV 501 | DDC 612.7/8—dc23
LC record available at https://lccn.loc.gov/2019029690

Contents

Preface

Anatomy & Physiology for Speech, Language, and Hearing, Sixth Edition, provides a sequential tour of the anatomy and physiology associated with speech, language, and hearing. We aspire to keep the content alive for students of today by providing not only basic anatomy and physiology, but also by forging the relationship between the structures and functions and the dysfunction that occurs when the systems fail. We know that students in audiology and speech-language pathology have their future clients in mind as they read this content, and we hope that by integrating information about pathology we can bring anatomy to life and to relevancy for you.

We have designed this text and the support materials to serve the upper division undergraduate or graduate student in the fields of speech-language pathology and audiology, and hope that it can serve you as a reference for your professional life as well. We aspire for it to be a learning tool and resource for both the developing and the accomplished clinician. We, the authors of this text, are first and foremost teachers ourselves. We are committed to the students within our professions and to the instructors who have made it their life work to teach them. Learning is a lifelong process, and our goal is to give instructors the tools to start students on that lifelong professional path and to inspire learning throughout your life. We know that learning is not a spectator sport because we continue to engage ourselves as learners. Our goal is to make the text and its ancillary materials as useful to 21st-century students as possible. This new edition not only provides students with great interactive study tools in the revised and renamed ANAQUEST study software, but also makes available a wealth of student and instructor resources to facilitate learning. We want you to be the best clinician and scientist you can be and sincerely hope that these materials move you along the path of your chosen career.

Organization

The text is organized around the five "classic" systems of speech and hearing: the respiratory, phonatory, articulatory/resonatory, nervous, and auditory systems. The respiratory system (involving the lungs) provides the "energy source" for speech, whereas the phonatory system (involving the larynx) provides voicing. The articulatory/resonatory system modifies the acoustic source provided by voicing (or other gestures) to produce the sounds we acknowledge as speech. The articulatory system is responsible for the mastication (chewing) and deglutition (swallowing) function, an increasingly important area within the field of speech-language pathology. The nervous system lets us control musculature, receive information, and make sense

of the information. Finally, the auditory mechanism processes speech and nonspeech acoustic signals received by the listener who is trying to make sense of her or his world.

There are few areas of study where the potential for overwhelming detail is greater than in the disciplines of anatomy and physiology. Our desire with this text and the accompanying software lessons is to provide a stable foundation upon which detail may be learned. In the text, we provide you with an introductory section that sets the stage for the detail to follow, and we bring you back to a more global picture with summaries. We have also provided derivations of words to help you remember technical terms.

New to the Sixth Edition

This new edition of *Anatomy & Physiology for Speech, Language, and Hearing, Sixth Edition* includes many exciting enhancements:

- Revised and updated physiology of swallowing includes discussion of orofacial-myofunctional disorders and other swallowing dysfunction arising from physical etiologies.
- An introduction to the effects of pathology on communication is included within each of the physical systems of communication.
- Many new photographs of specimens have been added, with a focus on a clear and accurate understanding of the classical framework of the speech, language, and hearing systems.
- *Clinical Notes* boxes link anatomy and physiology with disorders seen by speech-language pathologists and audiologists to provide real-world applications for students.
- The ANAQUEST study software is Internet-based and accessible on the PluralPlus companion website that comes with the text. ANAQUEST provides on-the-go learning, with animation lessons, simulations, and updates to content. The software now includes a set of video lab experiences narrated by new contributor Katrina Rhett, an anatomist and lecturer in the Department of Biological Sciences at Idaho State University. We have added three-dimensional views with animations that explore the important processes of hearing, phonation, respiration, swallowing, and more.

See the beginning of the textbook for instructions on how to access the PluralPlus companion website.

The PluralPlus companion website is divided into two areas: one housing materials for the instructor and the other just for students.

For the Instructor

The PluralPlus companion website contains a variety of tools to help instructors successfully prepare lectures and teach within this subject area. This comprehensive package provides something for all instructors, from those

teaching anatomy and physiology for the first time to seasoned instructors who want something new. The following materials have been made available just for instructors:

- An *Instructor's Manual* containing materials and suggested activities for the lecture and lab guides to facilitate learning outside of the classroom.
- A *test bank* with approximately 1,000 questions and answers, for use in instructor-created quizzes and tests.
- *PowerPoint lecture slides* for each chapter to use as in-class lecture material and as handouts for students.
- A version of the ANAQUEST study software created for upload to a Learning Management System (LMS).

For the Student

ANAQUEST study software comes with purchase of the textbook and can be accessed on the PluralPlus companion website. ANAQUEST software is your true partner in learning. The available labs give you the opportunity to examine structures and functions of the speech mechanism in an interactive digital environment. The ANAQUEST software is keyed to the text, reinforcing identification of the structures presented during lecture, but more importantly illustrating the function of those structures. An icon in the margin of the text indicates that you'll find related lessons and video labs in ANAQUEST, where you can examine speech physiology through the interactive manipulation of the structures under study, and learn the relationship of the body parts and how they function together. See the beginning of the textbook for the website URL and your access code.

J. Anthony Seikel
David G. Drumright
Daniel J. Hudock

About the Authors

J. Anthony (Tony) Seikel, PhD, is emeritus faculty at Idaho State University, where he taught graduate and undergraduate coursework in neuroanatomy and neuropathology over the course of his career in Communication Sciences and Disorders. He is coauthor of numerous chapters, books, and research publications in the fields of speech-language pathology and audiology. His current research is examining the relationship between orofacial myofunctional disorders and oropharyngeal dysphagia. Dr. Seikel is also coauthor of *Neuroanatomy & Neurophysiology for Speech and Hearing Sciences,* also published by Plural Publishing in 2018.

David G. Drumright, BS, grew up in Oklahoma and Kansas, taught electronics at DeVry for several years, then spent 20 years as a technician in acoustics and speech research. He developed many programs and devices for analysis and instruction in acoustics and speech/hearing. He has been semiretired since 2002, working on graphics and programming for courseware. He is also coauthor of *Neuroanatomy & Neurophysiology for Speech and Hearing Sciences,* published by Plural Publishing in 2018.

Daniel J. Hudock, PhD, CCC-SLP, is an Associate Professor of Communication Sciences and Disorders at Idaho State University who has taught courses on Anatomy & Physiology of the Speech and Hearing Mechanisms and Speech & Hearing Science for over a decade. He has published more than 30 articles and has given over 100 presentations. In his TEDx Talk (https://bit.ly/2oAYeKC) entitled "Please Let Me Finish My Sentence," he presents about his experience living with a stutter. Dr. Hudock is also the founding director of the Northwest Center for Fluency Disorders that offers an intensive interprofessional stuttering clinic with speech language pathologists collaborating with counselors and clinical psychologists through an Acceptance and Commitment Therapy (ACT) informed framework in the treatment of adolescent and adult stuttering, which is his main area of research.

About the Contributor

Katrina Rhett, MS, is an Assistant Lecturer in the Department of Biological Sciences at Idaho State University where she administers dissection-based and prosection-based human gross anatomy courses. She teaches undergraduate anatomy and physiology lab, graduate anatomy lab for the physical and occupational therapy programs, and advanced medical workshops. Prior to joining the faculty at Idaho State University, she taught undergraduate and medical human gross anatomy courses and conducted research in cardiovascular and muscular research labs at the University of Minnesota.

Acknowledgments

We are deeply indebted to our friends at Plural Publishing who have worked so hard to make this new edition happen. Frankly, we feel that we have returned home after a long time away, because this text began as a "twinkle in the eye" of Dr. Sadanand Singh, then owner of Singular Publishing. We were affiliated with another publisher for many years after, but are excited and relieved to have returned to our home in Plural Publishing, and to the capable and compassionate hands of Angie Singh and Valerie Johns. Angie and Val have had the vision to see this text through to its sixth edition, and we are forever grateful for their support and determination.

We would like to acknowledge the effort that reviewers put into their examination of our material and hope we have done justice to their work. Reviewers are the unsung heroes of textbook preparation. They put in long and often tedious hours, examining our work with an unflinching eye. The deadlines that they faced in reviewing the material for this sixth edition were daunting, and yet they persevered. We are very deeply indebted to them for their careful review and willingness to call our attention to areas that need refinement and improvement. We also are grateful for their keen insight and discernment, and hope that we have in some measure answered their suggestions. This textbook is written, quite literally, on their shoulders.

We also wish to acknowledge all those who have, over the course of the past few years, given us corrections and suggestions for improving the text. Patrick Walden, Mayrose McInerney, Nelson Roy, and Shawn Nissen have provided inspiration to us through their love of teaching. It has been inspiring to be once again in communication with Tanis Tranka and Lyn Russell. There are many other instructors and students with whom we have had the fortune to work and who have provided valuable feedback on the text, and we appreciate every one of you.

To you, our students, please realize that your future clients support your present intention and also will serve as your inspiration as you move through life. As speech-language pathologists and audiologists, we must acknowledge the tremendous debt we owe to the great researchers and teachers who have formed the profession, our colleagues with whom we consult and work, and, always, our clients, who have taught us more than any textbook could.

As authors, we must also acknowledge the source of our inspiration. We have been actively involved in teaching students in speech-language pathology and audiology for some time, and not a semester goes by that we don't realize how very dedicated our students are. There is something special about our field that attracts not just the brightest, but the most compassionate. You, students, keep us as teachers alive and vital. Thank you.

Introduction to the Learner

We continue to be impressed with the complexity and beauty of the systems of human communication. Humans use an extremely complex system for communication, requiring extraordinary coordination and control of an intensely interconnected sensorimotor system. It is our heartfelt desire that the study of the physical system will lead you to an appreciation of the importance of your future work as a speech-language pathologist or audiologist.

We also know that the intensity of your study will work to the benefit of your future clients and that the knowledge you gain through your effort will be applied throughout your career. We appreciate the fact that the study of anatomy is challenging, but we also recognize that the effort you put forth now will provide you with the background for work with the medical community.

A deep understanding of the structure and function of the human body is critical to the individual who is charged with the diagnosis and treatment of speech, language, and hearing disorders. As beginning clinicians, you are already aware of the awesome responsibility you bear in clinical management. It is our firm belief that knowledge of the human body and how it works will provide you with the background you need to make informed and wise decisions. We welcome you on your journey into the world of anatomy.

Using This Text

Use the elements found in the text to help guide you as you move along the path of your chosen career. The text offers the following features:

- **Margin Notes** identify important terminology, root words, and definitions, which are highlighted in color throughout each chapter. Other important terms are boldfaced in text to indicate that a corresponding definition can be found in the Glossary at the end of the book. Use these terms to study and prepare for tests and quizzes.

- **Clinical Notes** relate a topic directly to clinical experience to emphasize the importance of anatomy in your clinical practice. Gain insight into your chosen profession by using the topics discussed for research papers, to facilitate in-class discussion, and to complete homework assignments.

- **Photographs** provide a real-life look at the body parts and functions you are studying. Use these images as reference for accuracy in describing body systems, parts, and processes. Allow yourself to be amazed by the intricacies of human anatomy!

- **Illustrations and Graphs** provide visual examples of the anatomy, processes, and body systems discussed. Refer to the figures as you read the text to enhance your understanding of the specific idea or anatomical component being discussed. When reviewing for quizzes and tests, refer back to the figures for an important visual recap of the topics discussed.

- **Tables** highlight the various components, functions, structures, and pathologies of anatomical concepts related to what you might encounter in actual practice. Use these tables for quick reference to study and learn to relate your new anatomical knowledge to clinical experience.

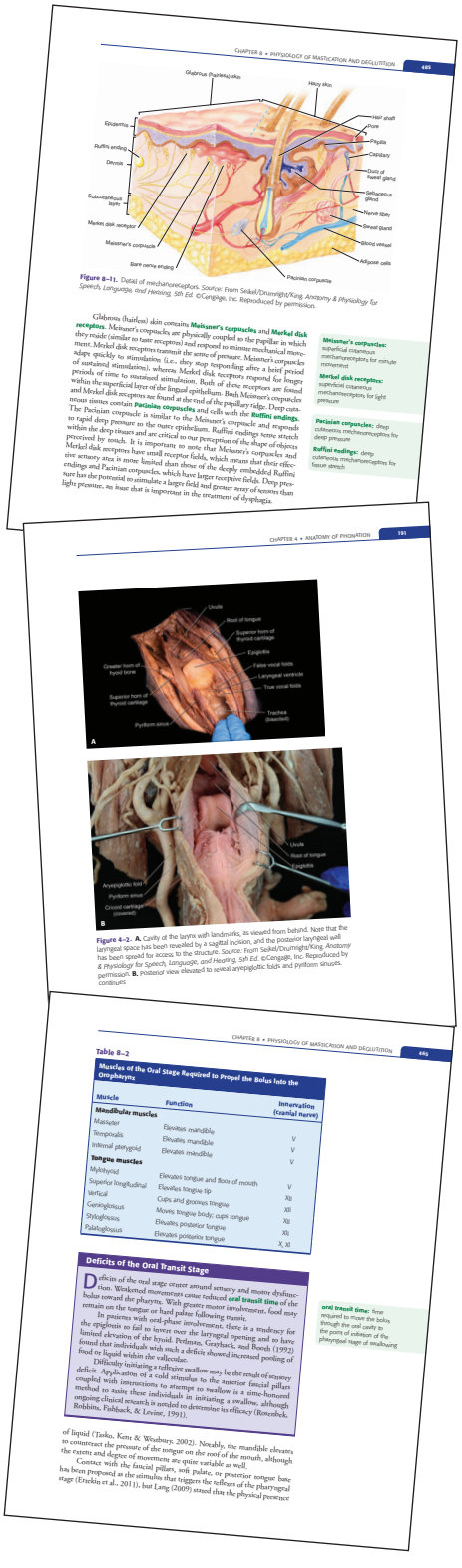

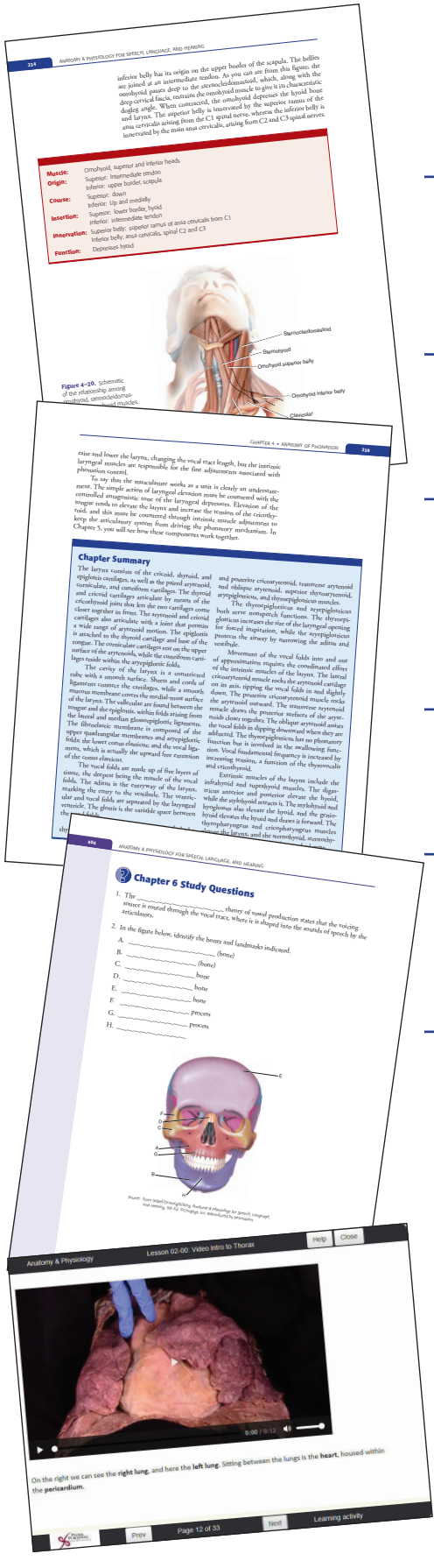

- **"To Summarize" sections** provide a succinct listing of the major topics covered in a chapter or chapter section. These summaries provide a helpful recap of the general areas where you should focus your time while reviewing for examinations.

- **Muscle Tables** describe the origin, course, insertion, innervation, and function of key muscles and muscle groups. Use these tables to stay organized and keep track of the numerous muscles studied in each chapter.

- **Chapter Summaries** provide precise reviews of content. The summary is offset from the running text to make it easily identifiable for quick review.

- **Study Questions and Answers** can be completed after reading a chapter to help you identify areas you may need to reread or focus on while studying. Complete the questions again as you review for a midterm or final examination to help keep the content fresh in your memory.

- A **Bibliography** with a comprehensive list of references at the end of each chapter offers great sources to start your research for a paper or class project.

- **Appendices** include an alphabetical listing of anatomical terms, useful combining forms, and listings of sensors and cranial nerves. You will also find a complete **Glossary** of all key terms found throughout the text.

- The **ANAQUEST** software labs and videos are self-paced, with frequent quizzes to help you examine the effectiveness of your study habits. If you spend two or three half-hour sessions per week with the ANAQUEST software, you will get the greatest benefit from your classes and readings. The software will also prove a great refresher in preparing for quizzes and examinations.

The authors wish to dedicate this text to the many clients we have known over our years of practice who have inspired us with their courage and wisdom. We also wish to dedicate this text to the students and faculty in speech and hearing who do the work of helping people with communication and swallowing difficulties. We have been blessed with our associations with you for many decades, and we know that audiologists and speech-language pathologists are compassionate and generous people who dedicate their lives to improving the well-being of others in what we, the authors, consider the most important aspect of life: communication. We thank you, the faculty and students of our fields, for your dedication.

—JAS, DGD, and DJH

I also dedicate the text to my four research mentors. Robert McCroskey, my first research mentor, would exclaim "data!" when he saw a printout, gleeful that he could pry some more meaning from observations. John Brandt gave me an "Occam's razor" with which to discern signal from noise, figure from ground. John Ferraro gave me a love of electrophysiological processes (as well as loan of his electrophysiological lab facility!) that has inspired my love of the hearing mechanism throughout my career. Kim Wilcox blessed me with passion for research and a sense of humor that has sustained me throughout my career. To all of these giants, I say "thank you" for the gift.

—Tony Seikel

I also dedicate the accompanying software to Professor Merle Phillips, who taught me something about audiology and a lot about life.

—David Drumright

I wish to dedicate my contributions to the text to the first author, "Tony," who has been a beloved colleague, mentor, and dear friend over the past several years. Tony's passion for the field, colleagues, teaching, and students knows no bounds as he has tirelessly and compassionately given of himself for the betterment of others. I would also like to dedicate my contributions to this book to the many speech-language pathologists, teachers, professors, students, friends, and family that have supported him along the way. There are no words that can fully express my gratitude and appreciation for the kindness and support shown to me. Thank you.

—Dan Hudock

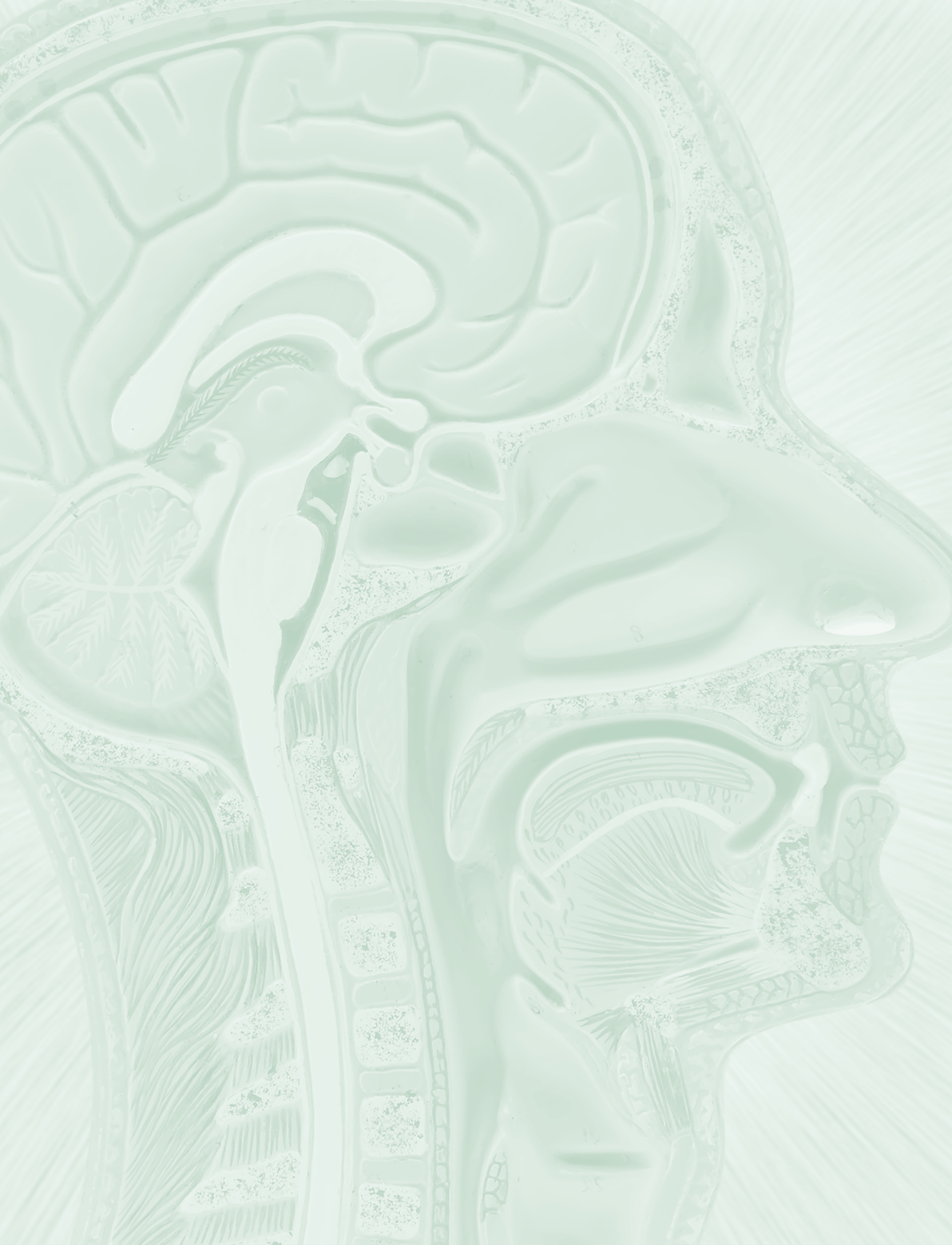

CHAPTER 1

Basic Elements of Anatomy

You are entering into study of the human body that has a long and rich tradition. We are fortunate to have myriad instruments and techniques at our avail for this study, but it has not always been so. You will likely struggle with arcane terminology that seems confusing and strange, and yet if you look closely, you will see what the early anatomists first saw. The amygdala of the brain is a small almond-shaped structure, and *amygdala* means almond. *Lentiform* literally means lens-shaped, and the lentiform nucleus is just that. The fact that the terminology remains in our lexicon indicates the accuracy with which our academic ancestors studied their field, despite extraordinarily limited resources.

This chapter provides you with some basic elements to prepare you for your study of the anatomy and physiology of speech, language, and hearing. We provide a broad picture of the field of anatomy and then introduce you to the basic tissues that make up the human body. Tissues combine to form structures, and those structures combine to form systems. This chapter sets the stage for your understanding of the new and foreign anatomical terminologies.

ANAQUEST LESSON

anatomy: Gr., anatome, **dissection**

dissection: L., dissecare, the process of cutting up

physiology: Gr., physis, nature; and logos, study; function of an organism

applied anatomy or **clinical anatomy:** application of anatomical study for the diagnosis and treatment of disease, particularly as it relates to surgical procedures

descriptive anatomy or **systemic anatomy:** anatomical specialty involving the description of individual parts of the body without reference to disease conditions

gross anatomy: study of the body and its parts as visible without the aid of microscopy

microscopic anatomy: study of the structure of the body by means of microscopy

surface anatomy or **superficial anatomy:** study of the body and its surface markings as related to underlying structures

Anatomy and Physiology

Anatomy refers to the study of the *structure* of an organism. **Physiology** is the study of the *function* of the living organism and its parts, as well as the chemical processes involved. **Applied anatomy** (also known as **clinical anatomy**) involves the application of anatomical study for the diagnosis and treatment of disease and surgical procedures. **Descriptive anatomy** (also known as **systemic anatomy**) is description of individual parts of the body without reference to disease conditions, viewing the body as a composite of systems that function together.

Gross anatomy studies structures that are visible without a microscope, while **microscopic anatomy** examines structures not visible to the unaided eye. **Surface anatomy** (also known as **superficial anatomy**) studies the form and structure of the surface of the body, especially with reference to the organs beneath the surface (Agur & Dalley, 2012; Gilroy, MacPherson, & Ross, 2012; Rohen, Lutjen-Drecoll, & Yokochi, 2010; Standring, 2008).

developmental anatomy: study of anatomy with reference to growth and development from conception to adulthood

pathological anatomy: study of parts of the body with respect to the pathological entity

comparative anatomy: study of homologous structures of different animals

electrophysiological techniques: those techniques that measure the electrical activity of single cells or groups of cells, including muscle and nervous system tissues

cytology: Gr., kytos, cell; logos, study

histology: Gr., histos, web, tissue; logos, study

osteology: Gr., osteon, bone; logos, study

myology: Gr., mys, muscle; logos, study

arthrology: Gr., arthron, joint; logos, study

angiology: Gr., angio, blood vessels; logos, study

neurology: Gr., neuron, sinew, nerve; logos, study

Developmental anatomy deals with the development of the organism from conception (Moore, Persaud, & Torchia, 2013).

When your study examines disease conditions or structural abnormalities, you have entered the domain of **pathological anatomy**. When we make comparisons across species boundaries, we are engaged in **comparative anatomy**.

Examination of physiological processes may entail the use of a range of methods, from simply measuring forces exerted by muscles, to highly refined **electrophysiological techniques** that measure electrical activity of single cells or groups of cells, including muscle and nervous system tissues. For example, audiologists are particularly interested in procedures that measure the electrical activity of the brain caused by auditory stimuli (**evoked auditory potentials**). We rely heavily on descriptive anatomy to guide our understanding of the physical mechanisms of speech and to aid our discussion of its physiology (e.g., Duffy, 2012). Study of pathological anatomy occurs naturally as you enter your clinical process, because many of the acquired conditions speech-language pathologists or audiologists work with arise from pathological changes in structure.

We will need to call on knowledge from related fields to support your study of anatomy and physiology. **Cytology** is the discipline that examines structure and function of cells; **histology** is the microscopic study of cells and tissues. **Osteology** studies structure and function of bones, while **myology** examines muscle form and function. **Arthrology** studies the joints uniting bones, and **angiology** is the study of blood vessels and the lymphatic system. **Neurology** is the study of diseases of the nervous system.

Teratogens

A **teratogen** or teratogenic agent is anything causing teratogenesis, the development of a severely malformed fetus. For an agent to be teratogenic, its effect must occur during prenatal development.

Because the development of the fetus involves the proliferation and differentiation of tissues, the timing of the teratogen is particularly critical. The heart undergoes its most critical period of development from the third embryonic week to the eighth, while the critical period for the palate begins around the fifth week and ends around the 12th week. The critical period for neural development stretches from the third embryonic week until birth. These critical periods for development mark the points at which the developing human is most susceptible to insult. An agent destined to have an effect on the development of an organ or system will have its greatest impact during that critical period.

Many teratogens have been identified, including organic mercury (which causes cerebral palsy, mental retardation, blindness, cerebral atrophy, and seizures), heroin and morphine (causing neonatal convulsions, tremors, and death), alcohol (fetal alcohol syndrome, mental retardation, microcephaly, joint anomalies, and maxillary anomalies), and tobacco (growth retardation), to name just a few.

To summarize:

- **Anatomy** is the study of the structure of an organism; **physiology** is the study of function.
- **Descriptive anatomy** relates the individual parts of the body to functional systems.
- **Pathological anatomy** refers to changes in structure as they relate to disease.
- **Gross** and **microscopic anatomy** refer to levels of visibility of structures under study.
- **Developmental anatomy** examines growth and development of an organism.
- **Cytology** and **histology** study cells and tissues, respectively. **Myology** examines muscle form and function.
- **Arthrology** refers to the study of the joint system for bones, while **osteology** is the study of form and function of bones.
- **Neurology** refers to the study of diseases of the nervous system.

Terminology of Anatomy

Terminology allows us to communicate relevant information concerning the location and orientation of various body parts and organs, so clarity of terminology is of the utmost importance in the study of anatomy. Terminology also links us to the historic roots of this field of study. To the budding scholar of Latin or Greek, learning the terms of anatomy is an exciting reminder of our linguistic history. To the rest of us, the terms we are about to discuss may be less easily digested but are nonetheless important.

As you prepare for your study of anatomy, please realize that this body of knowledge is extremely hierarchical. *What you learn today will be the basis for what you learn tomorrow.* Not only are the terms the bedrock for understanding anatomical structures, but also mastery of their usage will let you gain the maximum benefit from new material presented.

Terms of Orientation

In the **anatomical position**, the body is erect, and the palms, arms, and hands face forward, as shown in Figure 1–1A. Terms of direction assume this position. The body and brain (and many other structures) are seen to have axes (plural of axis) or midlines from which other structures arise. The **axial skeleton** is the head and trunk, with the spinal column being the axis, while the **appendicular skeleton** includes the upper and lower limbs. The **neuraxis**, or the axis of the brain, is slightly less straightforward due to morphological changes of the brain during development. The embryonic nervous system is essentially tubular, but as the cerebral cortex develops, a

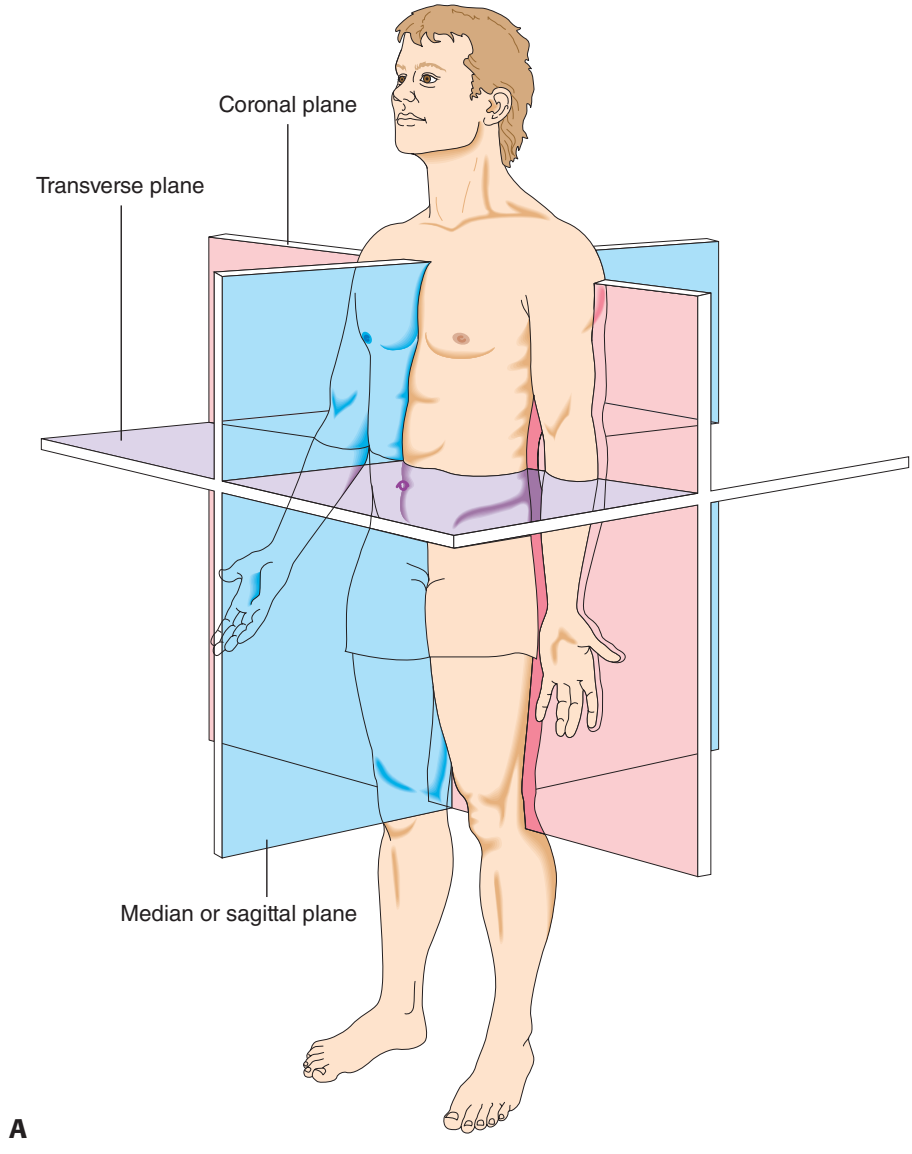

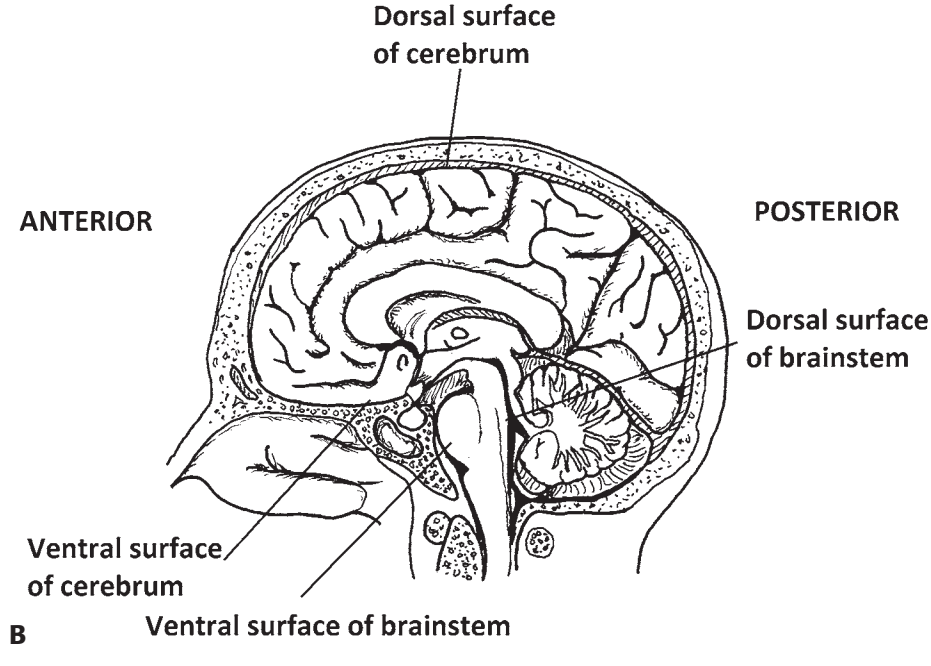

Figure 1–1. A. Terms and planes of orientation. *Source:* From Seikel/Drumright/King. *Anatomy & Physiology for Speech, Language, and Hearing, 5th Ed.* ©Cengage, Inc. Reproduced by permission. **B.** The neuraxis of the brain. *Source:* From *Neuroanatomy & Neurophysiology for Speech, Language and Hearing* by Seikel, J. A., Konstantopoulos, K. & Drumright, D. G. Copyright © 2020 Plural Publishing, Inc. *continues*

C

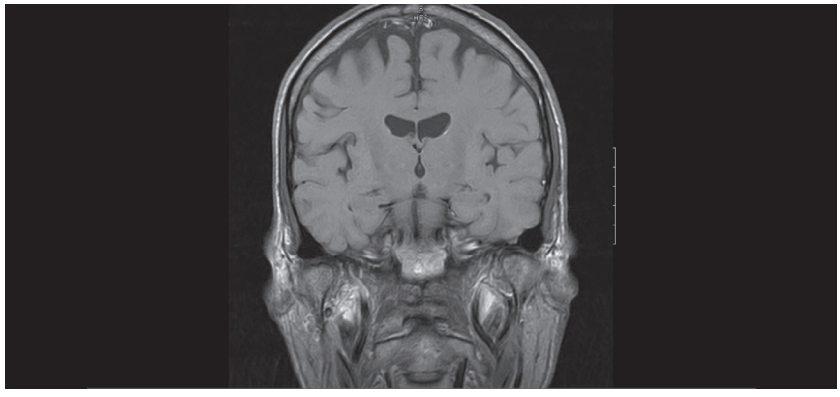

D

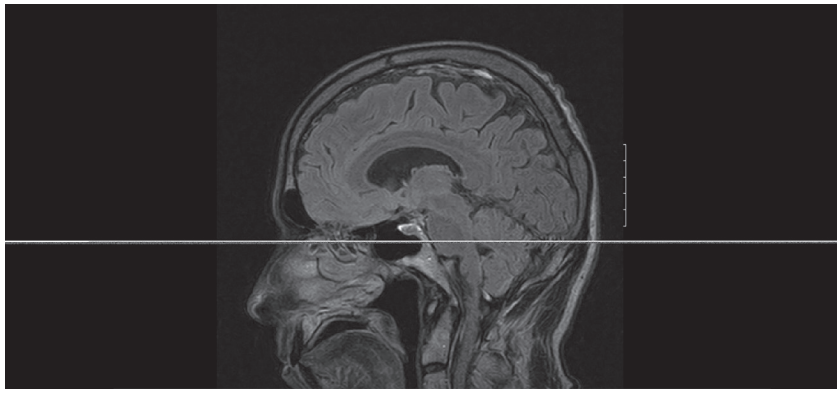

E

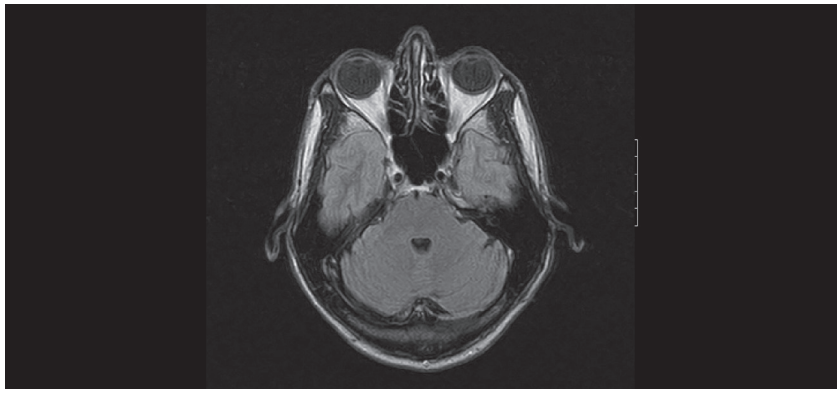

Figure 1–1. *continued* **C.** Coronal section through the brain and skull using magnetic resonance imaging (MRI). **D.** Sagittal or median section through the brain and skull using MRI. **E.** Transverse section through the brain and skull using MRI. *Source:* From Seikel/Drumright/King. *Anatomy & Physiology for Speech, Language, and Hearing, 5th Ed.* ©Cengage, Inc. Reproduced by permission. *continues*

flexure occurs and the telencephalon (the region that will become the cerebrum) folds forward. As a result, the neuraxis assumes a T-formation (Moore et al., 2013). The spinal cord and brain stem have dorsal (back) and ventral (front) surfaces corresponding to those of the surface of the body. Because the cerebrum folds forward, the dorsal surface is also the superior surface, and the ventral surface is the inferior surface. Most anatomists avoid this confusing state by referring to the ventral and dorsal surfaces of the embryonic brain as inferior and superior surfaces, respectively (Figure 1–1G).

Some terms are related to the physical orientation of the body (such as *vertical* or *horizontal*). Other terms (such as *frontal*, *coronal*, and *longitudinal*) refer to planes or axes of the body and are therefore insensitive to the position of the body.

Those of you who play cards may remember "ante up," meaning "put your money up front!" You may remember the term antebellum, meaning "before the war."

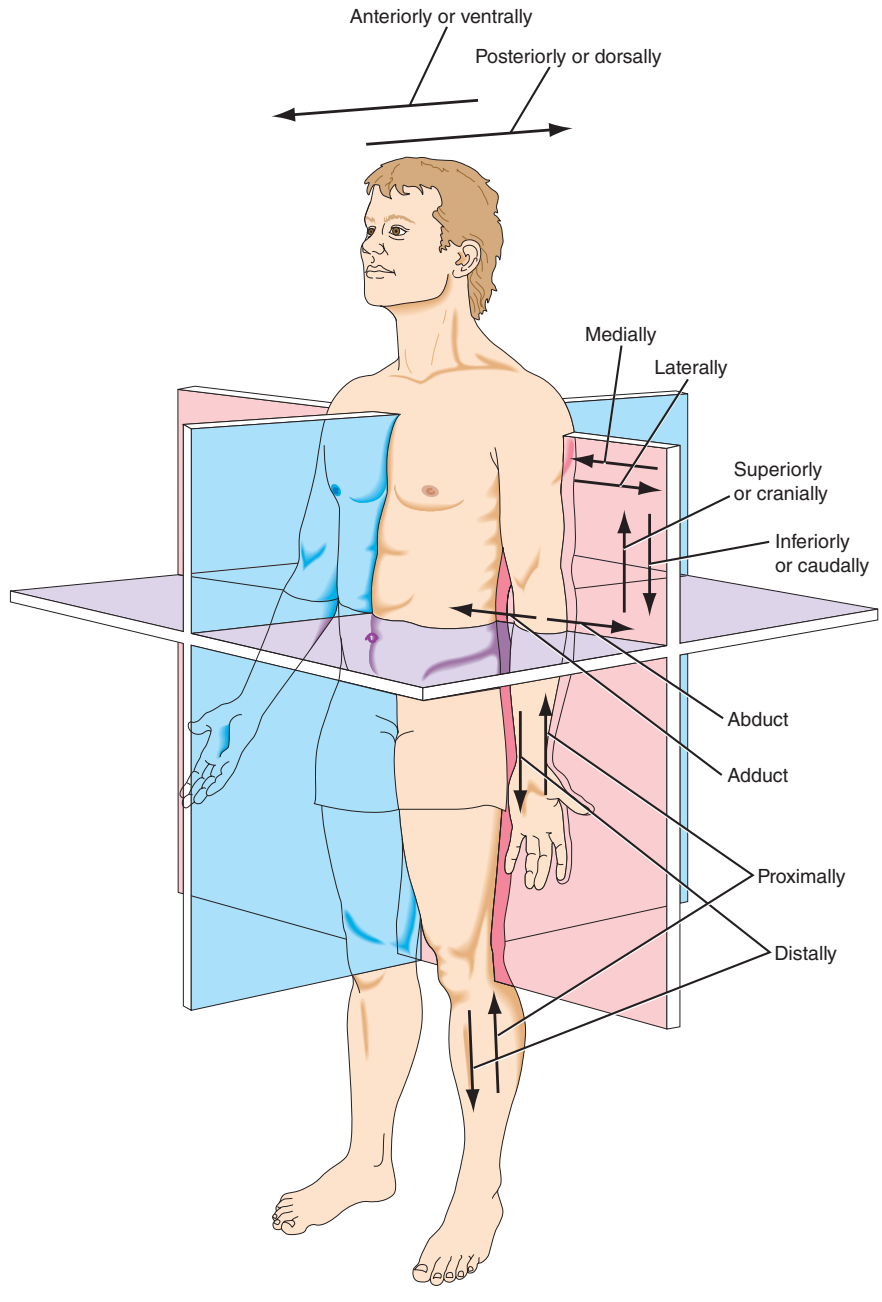

Figure 1–1. *continued*
F. Terms of movement. *Source:* From Seikel/Drumright/King. *Anatomy & Physiology for Speech, Language, and Hearing, 5th Ed.* ©Cengage, Inc. Reproduced by permission. *continues*

F

frontal section or **frontal view:** divides body into front and back halves

midsagittal section: an anatomical section that divides the body into left and right halves in the median plane

sagittal section: divides the body or body part into right and left halves

You may think of the following planes as referring to sections of a standing body, but they are actually defined relative to imaginary axes of the body. If you were to divide the body into front and back sections, you would have produced a **frontal section** or **frontal view**. If you cut the body into left and right halves, this would be along the median plane and it would produce **midsagittal sections**. A **sagittal section** is any cut that is parallel to the median plane and divides the body into left and right portions: The cut is in the sagittal plane. The **transverse plane** divides the body into upper and lower portions (this plane is often referred to by radiologists as *transaxial* or *axial*, and the radiological orientation always assumes you are looking from the feet toward the head). Figure 1–1A illustrates these sections. Armed with

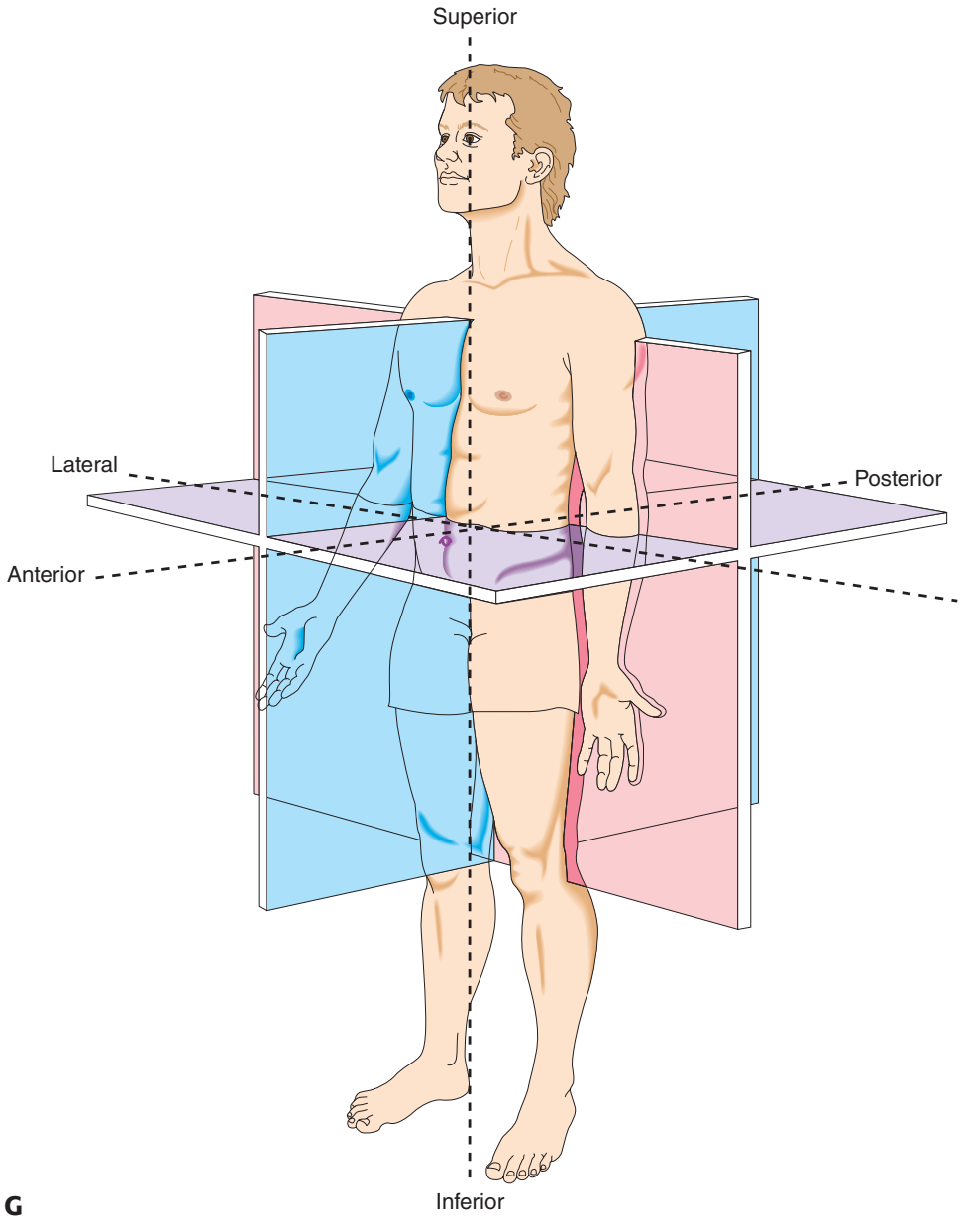

Figure 1–1. *continued*
G. Terms of spatial orientation. *Source:* From Seikel/Drumright/King. *Anatomy & Physiology for Speech, Language, and Hearing, 5th Ed.* ©Cengage, Inc. Reproduced by permission.

these basic planes of reference, you could rotate a structure in space and still discuss the orientation of its parts.

The term **anterior** refers to the front surface of a body. **Ventral** and anterior are synonymous for the standing human but have different meanings for a quadruped. The ventral aspect of a standing dog includes its abdominal wall, which is directed toward the ground. The anterior of the same dog would be the portion including the face.

The opposite of anterior is **posterior**, meaning toward the back. For those of us who walk on two feet "posterior" and "**dorsal**" both refer to the same region of the body. The posterior aspect of a four-footed animal differs from that of humans. Thus, you may refer to a muscle running toward the anterior surface, or a structure having a specific landmark in the posterior aspect. These terms are body-specific: Regardless of the position of the body,

anterior: L., front

ventral: pertaining to the belly or anterior surface

posterior: toward the rear

dorsal: pertaining to the back of the body

The term quadruped *refers to four-footed animals. The term* biped *refers to two-footed animals.*

rostral: L., rostralis, beak-like

anterior is toward the front of that body. The term **rostral** is often used to mean toward the head. If the term is used to refer to structures within the cranium, rostral refers to a structure anterior to another.

When discussing the course of a muscle, we often need to clarify its orientation with reference to the surface or level within the body. A structure may be referred to as **peripheral** (away from the center) to another. A structure is **superficial** if it is confined to the surface.

peripheral: relative to the periphery or away from

superficial: on or near the surface

deep: further from the surface

external: L., externus, outside

internal: within the body

distal: away from the midline

proximal: L., proximus, next to

When we say one organ is "**deep** to" another organ, we mean it is closer to the axis of the body. A structure may also be referred to as being **external** or **internal**, but these terms are generally reserved for cavities within the body. You may refer to an aspect of an appendicular structure (such as arms and legs) as being **distal** (away from the midline) or **proximal** (toward the root or attachment point of the structure).

A few terms refer to the actual present position of the body rather than a description based on the anatomical position. **Superior** (above, farther from the ground) and **inferior** (below, closer to the ground) are used in situations in which gravity is important. Superior can also indicate relative location. Structures that are near the head are referred to as superior or cranial, while those near the feet are referred to as inferior or caudal (the term *caudal* is more often used in this context when referring to an embryo). The terms **prone** (on the belly) and **supine** (on the back) are also commonly used in describing the present actual position.

prone: body in horizontal position with face down

supine: body in horizontal position with face up

lateral: toward the side

Often we need to describe the orientation of a structure relative to another structure. Some useful terms are **lateral** (related to the side) and **medial** (toward the median plane). If a point is closer to the median plane (the one that divides the body into left and right halves), it is medial to a point that is farther from that plane, which is lateral. So you would say, for instance, that the tongue is medial to the molars in the mandible because it is closer to the midline or median plane.

Terms of Movement

flexion: L., flexio, bending

extension: Gr., ex, out; L., tendere, to stretch

hyperextension: extreme extension

dorsiflexion: flexion that brings dorsal surfaces into closer proximity (syn., hyperextension)

plantar: pertaining to the sole of the foot

plantar flexion: flexion of toes of the foot

inversion: L., in, in; versio, to turn

eversion: L., ex, from, out; versio, to turn

palmar: pertaining to the palm of the hand

There are specialized terms associated with movement. **Flexion** refers to bending at a joint, usually toward the ventral surface. Flexion usually results in two ventral surfaces coming closer together. **Extension** is the opposite of flexion, being the act of pulling two ends farther apart. **Hyperextension**, or extending a joint too far, is sometimes referred to as **dorsiflexion**.

Use of flexion and extension with reference to feet and toes is a little more complex. **Plantar** refers to the sole of the foot, the flexor surface. If you rise on your toes, you are extending your foot, but the gesture is referred to as **plantar flexion** because you are bringing ventral surfaces closer together. A **plantar grasp reflex** is one in which stimulation of the sole of the foot causes the toes of the feet to "grasp." The term *dorsiflexion* may be used to denote elevation of the dorsum (upper surface) of the foot. You may turn the sole of your foot inward, termed **inversion**. A foot turned out is in **eversion**.

The term **palmar** refers to the palm of the hand, that is, the ventral (flexor) surface. The side opposite the palmar side is the dorsal side. If the

hand is rotated so that the palmar surface is directed inferiorly, it is **pronated** (remembering that in the prone position, one is lying on the stomach or ventral surface). **Supination** refers to rotating the hand so that the palmar surface is directed superiorly. A **palmar grasp reflex** is elicited by lightly stimulating the palm of the hand. The response is to flex the fingers to grasp. These and other useful terms and their definitions may be found in Appendixes A and B and the Glossary at the end of the book, as well as in a good medical dictionary.

pronated: to place an organism in the prone position

supination: to place an organism in the supine position

The names of muscles, bones, and other organs were mostly set down at a time in history when medical people spoke Latin and Greek as universal languages. The intention was to name parts unambiguously rather than to make things mysterious. Many of the morphemes left over from Latin and Greek are worth learning separately. When you come across a new term, you will often be able to determine its meaning from these components. For instance, when a text mentions an **ipsilateral** course for a nerve tract, you can see **ipsi** (same) and lateral (side) and conclude that the nerve tract is on the same side as something else. Your study of the anatomy and physiology of the human body will be greatly enhanced if it includes memorization of some of the basic word forms found in the appendixes.

ipsi: same

While you are studying the nomenclature of the field, do not let the plurals get you down. Fortunately, Latin is a well-organized language with a few general rules that will assist you in sorting through terminology. If a singular word ends in *a*, the plural will most likely be *ae* (*pleura*, *pleurae*). If a word ends in *us* (such as *locus*), the plural will end in *i* (*loci*). When the singular form ends in *um* (as in *datum* or *stratum*), the plural ending will change to *a* (*data* or *strata*).

Often you can feel comfortable using the Anglicized version (*hiatuses*), but do not assume everyone will. Many combined forms involve a possessive form, denoting ownership (the genitive case, in linguistic jargon): *corpus*, body; *corporum*, of the body. The English pronunciation of these forms is unfortunately less predictable and not universally adopted.

Parts of the Body

The human body can be described in terms of specific regions. The **thorax** is the chest region, and the **abdomen** is the region represented externally as the belly, or anterior abdominal wall. Together, these two components make up the **trunk** or **torso**. The **dorsal trunk** is the region we commonly refer to as the *back*. The area of the hip bones is known as the **pelvis**. Resting atop the trunk is the head or **caput**.

thorax: the part of the body between the diaphragm and the seventh cervical vertebra

abdomen: L., belly

dorsal trunk: the region commonly referred to as the back of the body

pelvis: the area formed by the bones of the hip area

The skull consists of two components: the **cranial portion**, the part of the skull that houses the brain and its components, and the **facial part**, the part of the skull that houses the mouth, pharynx, nasal cavity, and structures related to the upper airway and mastication (chewing).

cranial portion: the part of the skull that houses the brain and its components

facial part: the part of the skull that houses the mouth, pharynx, nasal cavity, and structures related to the upper airway and mastication

The upper and lower extremities are attached to the trunk. The **upper extremity** consists of the arm (from the shoulder to the elbow), the forearm, wrist, and hand. The **lower extremity** is made up of the thigh, leg, ankle,

upper extremity: portion of the body made up of the arm, forearm, wrist and hand

lower extremity: portion of the body made up of the thigh, leg, ankle, and foot

and foot. (In common usage, *arm* means from shoulder to hand and *leg* from thigh to foot.)

Within these components of the body are five enclosed spaces, or cavities, within which organs reside. Specific neuroanatomical cavities include the cranial cavity, in which the brain resides, and the vertebral canal, within which is found the spinal cord. Within the trunk are found the thoracic cavity (housing lungs and related structures), the pericardial cavity (housing the heart), and the abdominal cavity (housing the digestive organs).

To summarize:

- The **axial skeleton** consists of the trunk and head, whereas the **appendicular skeleton** comprises the upper and lower extremities.
- The **trunk** consists of the abdominal and thoracic regions.
- Anatomical terminology is the specialized set of terms used to define the position and orientation of structures.
- The **frontal plane** divides the body into front and back halves, whereas the **median** or **sagittal plane** divides the body into right and left halves. Sections that are parallel to these planes are referred to as **frontal sections** or **sagittal sections**, respectively.
- A **transverse section** divides the body into upper and lower portions.
- **Anterior** and **posterior** refer to the front and back surfaces of a body, respectively, as do **ventral** and **dorsal** for the erect human.
- **Superficial** refers to the surface of a body, while **peripheral** and **deep**, respectively, refer to directions toward and away from the surface.
- **Medial** refers to something closer to the median plane, while **lateral** refers to something farther from that plane.
- **Superior** refers to an elevated position, whereas **inferior** is closer to the ground.
- **Prone** and **supine** refer to being on the belly and back, respectively.
- **Proximal** refers to a point near the point of attachment of a free extremity or toward that point of attachment, and **distal** refers to a point away from the root of the extremity or away from that root.
- **Flexion** and **extension** refer to bending at a joint. Flexion refers to bringing ventral surfaces closer together, and extension is moving them farther apart.
- **Plantar** refers to the sole of the foot, while **palmar** refers to the palm of the hand. Both are ventral surfaces.

Building Blocks of Anatomy: Tissues and Systems

In the sections that follow, we present the building blocks of the physical system you are preparing to study. These blocks include the basic tissues, organs, structures made up of these tissues, and systems made up of the

organs. Let us turn our attention to the basic elements of which all bodies are composed.

Tissues

The building block of the body is the cell—living tissue that contains a nucleus and a variety of cellular material specialized to its particular function. Cells differ based on the type of **tissue** they comprise. Our study of anatomy will focus on muscle cells, nerve cells, cells that make up connective and epithelial tissue, and cells that combine to form the structures involved in speech and hearing.

tissue: L., texere, to weave

Types of Tissues

Four basic tissues constitute the human body, and variants of these combine to make up the structures of the body. These are epithelial, connective, muscular, and nervous tissues. These tissues have numerous subclasses, as shown in Table 1–1. Let us look at each tissue in turn.

Epithelial Tissue

Epithelial tissue refers to the superficial (outer) layer of mucous membranes and the cells constituting the skin, as well as the linings of major body cavities and all of the "tubes" that pass into, out of, and through the body. The hallmark of epithelial tissue is its shortage of intercellular material. This is in contrast to bone, cartilage, and blood, all of which have significant quantities of intercellular matter. The absence of intercellular material lets the epithelial cells form a tightly packed sheet that acts as a protective layer. Epithelia serve as a barrier to prevent or permit substances to pass to the structures being contained by them. For example, the epithelial lining of the vocal folds keeps the tissues from becoming dehydrated (a very important function, as any singer will attest).

epithelial tissue: the cells making up the skin and the superficial layer of mucous membranes, as well as linings of cavities of the body.

There are many layers of epithelium. We are most familiar with the surface covering of the human body, but epithelial tissue lines nearly all of the cavities of the body as well as the conduits that connect them. Some epithelial tissues are secretory (glandular epithelium), some allow for absorption (villi, the linings of our intestines), and others have **cilia** or hair-like protrusions that actively beat to remove contaminants from the epithelial surface (known as "beating ciliated epithelia") of the respiratory passageway. Generally, epithelial tissue can regenerate if damaged.

Cilia can be found on surfaces throughout the body and are unique in that they are motile, which means that their function involves movement. Cilia are found in the cavities of the respiratory passageway, within the ventricles of the brain, in the lining of the central canal in the spinal cord, as part of the olfactory receptor (sense of smell), and even in portions of the rods and cones of the retina. Ciliated tissues share a common characteristic, which is the beating behavior of their hair-like protrusions. The cilia move rapidly in one direction and more slowly in the opposite direction. In this manner, they are able to move materials from one location to another during

Table 1–1

Tissue Types
I. Epithelial
A. Simple epithelium: Single layer of cells
Squamous (pavement) epithelium: Single layer of flat cells; linings of blood vessels, heart, alveoli, lymphatic vessels
Cuboidal (cubical) epithelium: Cube-shaped; secretory function in some glands, such as thyroid
Columnar epithelium: Single layer, cylindrical cells; inner lining for stomach, intestines, gall bladder, bile ducts
Ciliated epithelium: Cylindrical cells with cilia; lining of nasal cavity, larynx, trachea, bronchi
B. Compound epithelium: Different layers of cells
Stratified epithelium: Flattened cells on bed of columnar cells; epidermis of skin, lining of mouth, pharynx, esophagus; conjunctiva
Transitional epithelium: Pear-shaped cells; lining of bladder, etc.
C. Basement membrane (baseplate)
Made predominantly of collagen; underlies epithelial tissue; serves stabilizing and other functions, including joining epithelial and connective tissues
II. Connective
A. Areolar: Elastic; supports organs; between muscles
B. Adipose: Cells with fat globules; between muscles and organs
C. White fibrous: Strong, closely packed; ligaments binding bones; periosteum covering bone; covering of organs; fascia over muscle
D. Yellow elastic: Elastic; in areas requiring recoil, such as trachea, cartilage, bronchi, lungs
E. Lymphoid: Lymphocytes; make up lymphoid tissue of tonsils, adenoids, lymphatic nodes
F. Cartilage: Firm and flexible
Hyaline cartilage: Bluish white and smooth; found on articulating surfaces of bones, costal cartilage of ribs, larynx, trachea, and bronchial passageway
Fibrocartilage: Dense, white, flexible fibers; intervertebral disks; between surfaces of knee joints
Yellow (elastic) cartilage: Firm elastic; pinna, epiglottis
G. Blood: Corpuscles (cells: red, white), platelets, blood plasma
H. Bone: Hardest connective tissue
Compact bone: Has haversian canal, lamellar structure
Cancellous (spongy) bone: Spongy appearance, larger haversian canal, red bone marrow producing red and white blood cells and plasma
III. Muscular
A. Striated: Skeletal, voluntary
B. Smooth: Muscle of internal organs, involuntary
C. Cardiac: Combination of striated and smooth, involuntary
IV. Nervous
A. Neurons: Transfer information; communicating tissue
B. Glial cells: Nutrient transfer; blood–brain barrier

Compiled from taxonomy from *Foundations of Anatomy and Physiology* (2nd ed.) by J. S. Ross & K. J. W. Wilson, 1966, pp. 1–32. Baltimore, MD: Williams & Wilkins.

a slow stroke but return to their original position using a rapid stroke. This extraordinary function removes pollutant-laden mucus from the respiratory passageway and moves molecules of materials onto (and off of) the surface of an olfactory sensor. While this may seem at first glance to be an esoteric discussion, realize that the same motile elements that drive cilia to move "gunk" from the lungs also provide the most exciting discovery in the 20th century in hearing science, which is the active movement of the outer hair cells of the cochlea in response to sound stimulation.

A **baseplate** or **basement membrane** made predominantly of collagen underlies epithelial tissue and serves a number of functions, depending on the location of the epithelium. Basement membrane may act as a filter (for instance, in the kidneys) or stabilize the epithelial tissue (as in the juncture of connective tissue with epithelium). The baseplate is important in directing growth patterns for epithelial cells.

baseplate or **basement membrane:** the tissue that underlies the epithelium, which is made predominantly of collagen

Epithelial tissue provides a barrier to some material. For instance, the surface epithelium we know as *skin* is an amazing barrier to hostile agents in the environment (although it is not impermeable, particularly to modern solvents, many of which can pass quickly through the epithelial barrier). Epithelia can protect skin from dehydration and leakage of fluid. Specialized versions of epithelia can also have a secretory function such as secreting epithelia that make up glands or serve as sensory elements such as the sensory epithelia of the olfactory system (sense of smell).

Connective Tissue

Connective tissue is perhaps the most complex of the tissue categories, being specialized for the purposes of support and protection. Unlike epithelium, connective tissue is composed predominantly of intercellular material, known as the **matrix**, within which the cells of connective tissue are bound. Connective tissue may be solid, liquid, or gel-like. The matrix is the defining property of a specific connective tissue.

matrix: an intercellular material that holds or constrains another material

interstitial: L., interstitium, space or gap in tissue

Areolar tissue, also known as *loose connective tissue*, is supportive by nature. This elastic material is found between muscles and as a thin, membranous sheet between organs. It fills the **interstitial** space between organs, and its fibers form a mat or weave of flexible collagen. **Adipose** tissue is areolar tissue that is highly impregnated with fat cells. **Lymphoid tissue** is specialized connective tissue found in tonsils and adenoids. A **mucous** membrane, which arises from an embryonic mucosal tissue, lines many cavities. This membrane includes an epithelial lining that may have mucosal glands that secrete mucus, loose connective tissue (referred to as the *lamina propria*), and a thin layer of muscle, which may help move material within the cavity. **Mucus** is a secretion by specialized cells that derive from epithelium.

fibrous tissue: tissue that binds structures together and that may contain combinations of fiber types

white fibrous tissue: connective tissue that is strong and dense, providing the means for binding structures of the body

yellow (elastic) cartilage: cartilaginous connective tissue that has reduced collagen and increased numbers of elastic fibers.

Fibrous tissue binds structures together and may contain combinations of fiber types. **White fibrous tissue** is strong, dense, and highly organized. It is found in ligaments that bind bones together, as well as in the fascia that encases muscle. **Yellow elastic** tissue is found where connective tissue must return to its original shape after being distended, such as in the cartilage of the trachea or bronchial passageway. **Yellow cartilage** has less collagen,

endowed rather with elastic fibers. It is found in the structure of the outer ear (pinna), nose, and the epiglottis, a cartilage of the larynx.

Cartilage becomes quite important as we discuss the respiratory system (Chapter 2), the phonatory system (Chapter 4), and the articulatory/resonatory system (Chapter 6).

Cartilage is an important tissue because it has unique properties of strength and elasticity. The **tensile strength** of cartilage keeps the fibers from being easily separated when pulled, while the **compressive strength** lets it retain its form by being resistant to crushing or compressive forces. **Hyaline cartilage** is smooth and has a glassy, blue cast. It provides a smooth mating surface for the articulating surfaces of bones, as in the cartilaginous portion of the rib cage. The larynx, trachea, and bronchial passageway are also made of hyaline cartilage. **Fibrocartilage** contains collagenous fibers, providing the cushion between the vertebrae of the spinal column, as well as the mating surface for the temporomandibular joint between the lower jaw and the skull. Fibrocartilage acts as a shock absorber and provides a relatively smooth surface for gliding.

fibrocartilage: connective tissue fibers that contain collagen, providing a cushioning for structures

blood: connective tissue comprising of plasma and blood cells suspended in this plasma matrix

bone: the hardest of the connective tissues

compact bone: bone characterized microscopically by its lamellar or sheet-like structure

spongy bone: bone that appears porous; contains marrow that produces red and white blood cells

fibroblast: L., fibra, fibrous; Gr., blastos, germ; tissue element able to synthesize and secrete protein

Blood is also a connective tissue. The fluid component of blood is called *plasma*, and blood cells (including red and white corpuscles) are suspended in this matrix. The blood cells arise from within the marrow of another type of connective tissue, bone.

Bone is the hardest of the connective tissues. The characteristic hardness of bone is a direct function of the inorganic salts that make up a large portion of bone. Bone is generally classified as being compact or spongy. **Compact bone** is characterized microscopically by its lamellar or sheet-like structure, whereas **spongy bone** looks porous. Spongy bone contains the marrow that produces red and white blood cells as well as the blood plasma matrix.

The protective function of connective tissue is played out by several different classes of cells. **Fibroblasts** are responsible for production of the extracellular matrix, so they are able to synthesize and secrete protein. Another important function of fibroblasts is wound repair: Fibroblasts infiltrate a wound site and lay down a matrix, which becomes infiltrated with a vascular supply to become granulations. In this manner, the wound area is closed and sealed, and blood supply is restored to the wound region. The matrix ultimately contracts as a result of contractile properties of the fibroblast, at least partially closing the wound area.

Macrophages comprise another very important class of healing connective tissue. They are responsible for the collection of waste or necrotic (dead) tissue. Macrophages engulf bacteria and dead tissue, and digest them by secreting soluble proteins. The process of digestion and removal of dead tissue is a critical stage preceding regeneration of tissue.

Two other important protective cell types include lymphocytes and mast cells. B-lymphocytes arise from bone marrow and are stimulated by the presence of foreign matter to proliferate within lymph tissue. They ultimately generate and secrete antibodies to defend against a viral attack. T-lymphocytes also arise from bone marrow but end up in the thymus. Their proliferation is stimulated by viruses, and their job is to seek and destroy viral agents. Mast cells are found in loose connective tissues and some organs. They provide the first response to irritation, namely, inflammation. Apparently, the inflammation of connective tissues promotes migration of other

cells to the damaged site for protective purposes. This protective function can go awry, as seen in anaphylactic shock, which is a runaway hypersensitive inflammatory reaction.

Muscular Tissue

Muscle is specialized contractile tissue that has muscle fibers capable of being stimulated to contract. Muscle is generally classified as being striated, smooth, or cardiac (Figure 1–2). **Striated** muscle, which has a striped appearance on microscopic examination, is more commonly known as **skeletal muscle** because it is used to move skeletal structures. It is also known as **voluntary** or **somatic muscle**, because it can be moved in response to conscious, voluntary processes. In contrast, **smooth muscle**, which includes the visceral muscular tissue of the digestive tract and blood vessels, is generally sheet-like, with spindle-shaped cells. **Cardiac muscle** is composed of cells that interconnect in a net-like fashion. Smooth and cardiac muscle are generally outside of voluntary control, relegated to the **autonomic** or involuntary nervous system.

striated: L., stria, striped; streaked

smooth muscle: muscle that is found in the **viscera**, including digestive tract and blood vessels

viscera: L., body organs

cardiac muscle: muscle of the heart, composed of cells that interconnect in a net-like fashion

autonomic: Gr., autos, self; nomos, law; self-regulating

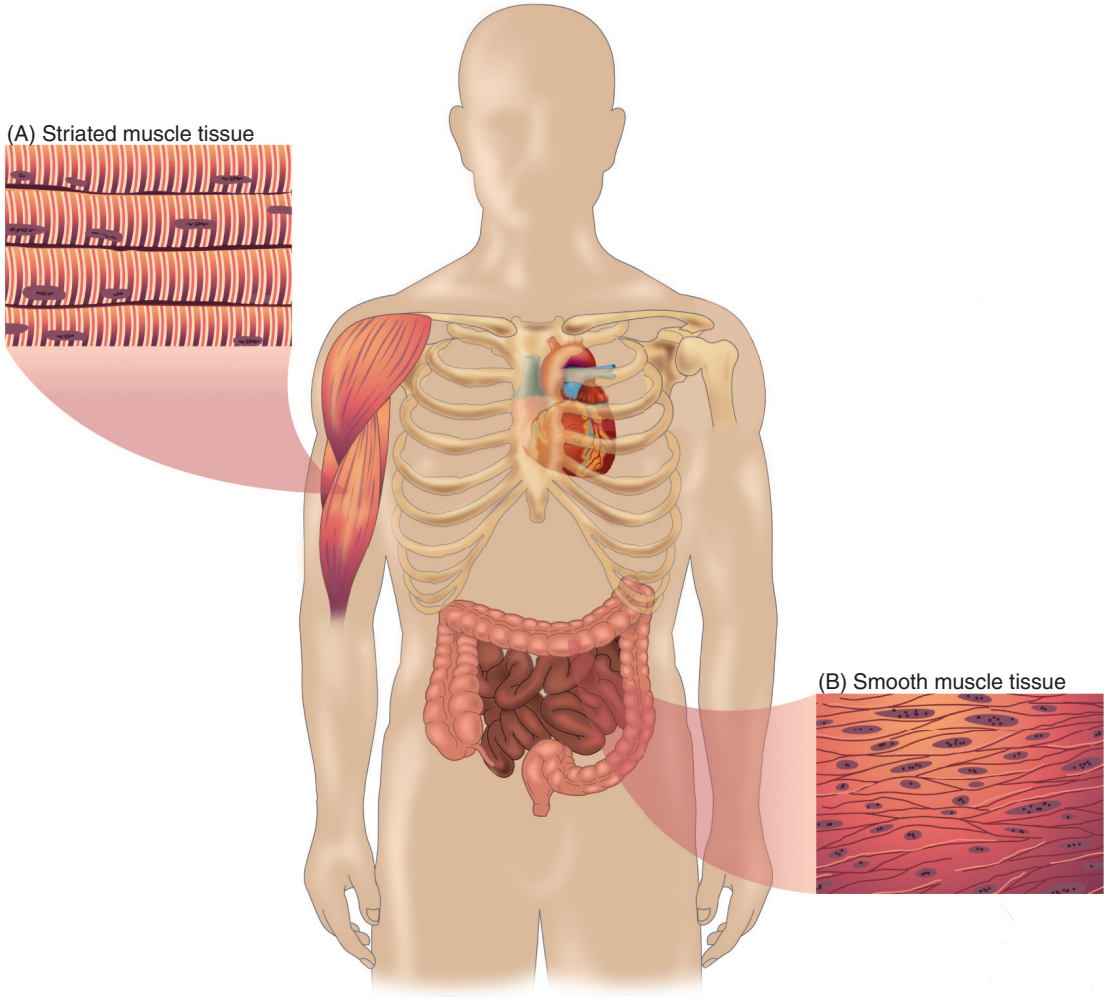

Figure 1–2. Striated and smooth muscle. *Source:* From Seikel/Drumright/King. *Anatomy & Physiology for Speech, Language, and Hearing, 5th Ed.* ©Cengage, Inc. Reproduced by permission.

nervous tissue: highly specialized communicative tissue consisting of neurons or nerve cells

Nervous Tissue

Nervous tissue is a highly specialized communicative tissue. Nervous tissue consists of **neurons** or nerve cells that take on a variety of forms. The function of nervous tissue is to transmit information from one neuron to another, from neurons to muscles, or from sensory receptors to other neural structures.

To summarize:

- Four **basic tissues** constitute the human body: epithelial, connective, muscular, and nervous.
- **Epithelial tissue** includes the surface covering of the body and linings of cavities and passageways. **Mucous membranes** arise from epithelial tissue, and are specialized structures that line cavities and sometimes secrete mucus.
- **Connective tissue** varies as a function of the intercellular material (matrix) surrounding it.
- **Areolar connective tissue** is loose and thin. **Adipose tissue** is areolar tissue with significant fat deposits.
- White **fibrous connective** and **yellow elastic tissues** are found in ligaments, tendons, and cartilage.
- **Cartilage** has both tensile and compressive strength and is elastic (fibers of cartilage resist being torn apart or crushed, and cartilage tends to return to its original shape upon being deformed).
- **Hyaline cartilage** is smooth, while fibrocartilage provides a collagenous cushion between structures.
- **Blood** is a fluid connective tissue, whereas **bone** is a highly dense connective tissue.
- **Muscular** is the third type of tissue, consisting of **voluntary** (striated), **involuntary** (smooth), and **cardiac** muscle.
- **Nervous tissue** is specialized for communication.

Tissue Aggregates

organs: aggregates of tissues of the body with functional utility

muscles: contractile tissue

The basic body tissues (epithelial, connective, muscular, and nervous) are combined to form larger structures. For instance, **organs** are aggregates of tissues with **functional unity**, by which we mean that the tissues of an organ all serve the same general purpose (e.g., the heart, lungs, or tongue). In the same sense, we speak of **muscles** (e.g., the diaphragm) as being structures made up of contractile muscular tissue, and the muscles must be attached to bone or cartilage in some fashion. Let us examine some of the larger organizational units.

Fascia

fascia: L., band

Fascia, which surrounds organs, is a sheet-like membrane that may be either dense or nearly transparent, thin or thick. Striated muscle is surrounded

by **perimysium**, fascia that is sufficiently thick that the muscle cannot be seen clearly through it. Perimysium is usually sheet-like and interwoven in structure, and does not have the highly organized and compact form that tendons take on. It is the packing material around organs, peripheral nerves, and blood vessels, providing some physical isolation and stability.

Ligaments

The term **ligament** refers specifically to binding together structures of the body. Visceral ligaments bind organs together or hold structures in place. **Ligaments** must withstand great pressure because they typically bind bone to bone. To achieve a secure binding the connective tissue fibers course in the same direction, giving ligaments great tensile strength. Most ligaments have little stretch, although some (such as the posterior spinal cord ligaments) are endowed with elastic fibers to permit limited stretching. Ligaments that stretch appear yellow, while inelastic ligaments have a white cast.

ligaments: connective tissues that bind bone to bone

Tendons

Tendons provide a means of attaching muscle to bone or cartilage (Figure 1–3). The fibers of tendons are arrayed longitudinally (as opposed to interwoven or matted), giving them great tensile strength but reduced compressive strength. Because tendon is actually part of the muscle, it always binds muscle to another structure (typically bone), attaching to the connective tissue of that skeletal structure. Tendons tend to have the **morphology** (or form) of the muscles they serve. Compact, tubular muscles usually have long, thin tendons. Flat muscles, such as the diaphragm, generally have flat tendons. The microscopic structure of a tendon makes it quite resistant to damage. Because the collagenous fibers intertwine, the forces placed on the tendon are distributed throughout the entire bundle of fibers. Tendons may stretch up to 10% of their length without being injured. They are flexible, so they can course around bone as needed, and have a blood supply and a sensory nerve supply.

morphology: Gr., morphe, form

When a tendon is sheet-like, it is called an **aponeurosis**. Aponeuroses greatly resemble fascia but are much denser. In addition, an aponeurosis

aponeurosis: Gr., apo, from; neuron, nerve; sheet-like tendon

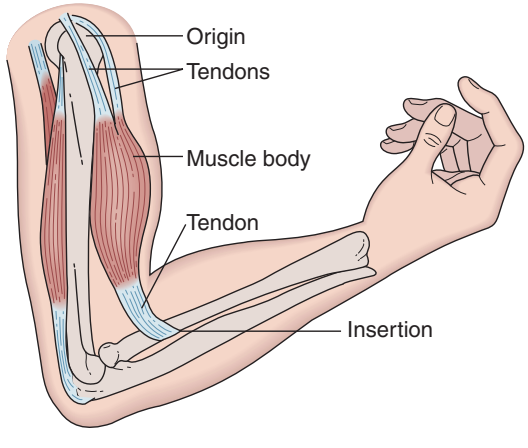

Figure 1–3. Tendons attaching muscle to bone. *Source:* From Seikel/Drumright/King. *Anatomy & Physiology for Speech, Language, and Hearing, 5th Ed.* ©Cengage, Inc. Reproduced by permission.

Osteoporosis

Osteoporosis is a condition wherein bone becomes increasingly porous due to loss of calcium. The reduction in calcium may be the result of aging or may arise from vitamin D deficiency, as in osteomalacia. Loss of calcium may also arise from disuse, as found in individuals confined to bed during illness. Individuals with osteoporosis are particularly susceptible to bone fractures from normal application of force. The elderly individual who has fallen and broken a hip may actually have broken the hip prior to the fall. An individual with osteoporosis may break ribs while coughing. Osteoporosis may be localized, as seen in the bones of the skull in Paget's disease (osteitis deformans).

retains the longitudinal orientation of the connective tissue fibers, whereas a fascia is made up of matted fibers.

The dense packing of longitudinal fibers makes tendons quite strong. A tendon can withstand pulling of more than 8,000 times the stretching force that a muscle the same diameter can. In fact, the tendon for a given muscle is able to withstand at least twice the pulling force of the muscle itself. That is, a sudden pull on a muscle will damage the muscle itself or the musculotendinous junction well before the tendon itself is actually damaged.

Bones

articulation: the point of union between two structures

Bones and cartilage have an interesting relationship. Developing bone typically has a portion that is cartilage, and all bone begins as a cartilaginous mass. Many points of **articulation** (or joining) between bones are composed of cartilage, because cartilaginous surfaces are smoother and glide across each other more freely than surfaces of bone. Likewise, cartilage replaces bone where elasticity is beneficial. We see this in the cartilaginous portion of the rib cage, in the cartilage of the larynx, and in the nasal cartilages. As cartilage becomes impregnated with inorganic salts, it begins to harden, ultimately becoming bone.

Bones provide rigid skeletal support and protect organs and soft tissues. Thirty percent of a bone is collagen, providing great tensile strength. The rigidity and compressive strength of bone tissue comes from the even greater proportion of calcium deposited within it. Indeed, bones in older individuals become more susceptible to compression as a result of loss of calcium through the aging process.

Bones are broadly characterized by length (long or short) or shape (flat), or generally as having irregular morphology. The **periosteum** (fibrous membrane covering of a bone) extends along its entire surface except regions with cartilage. This outer periosteum layer is most tightly bound to the bone at the tendinous junctures. Although the outer periosteum layer is tough and fibrous, the inner layer of periosteum contains fibroblasts that facilitate bone repair.

Blood cell production occurs within the cavities of the spongy bone trabeculae (trabeculae are supporting "beams" of a structure). As you can see from Figure 1–4, the cavities within the spongy bone are protected by the

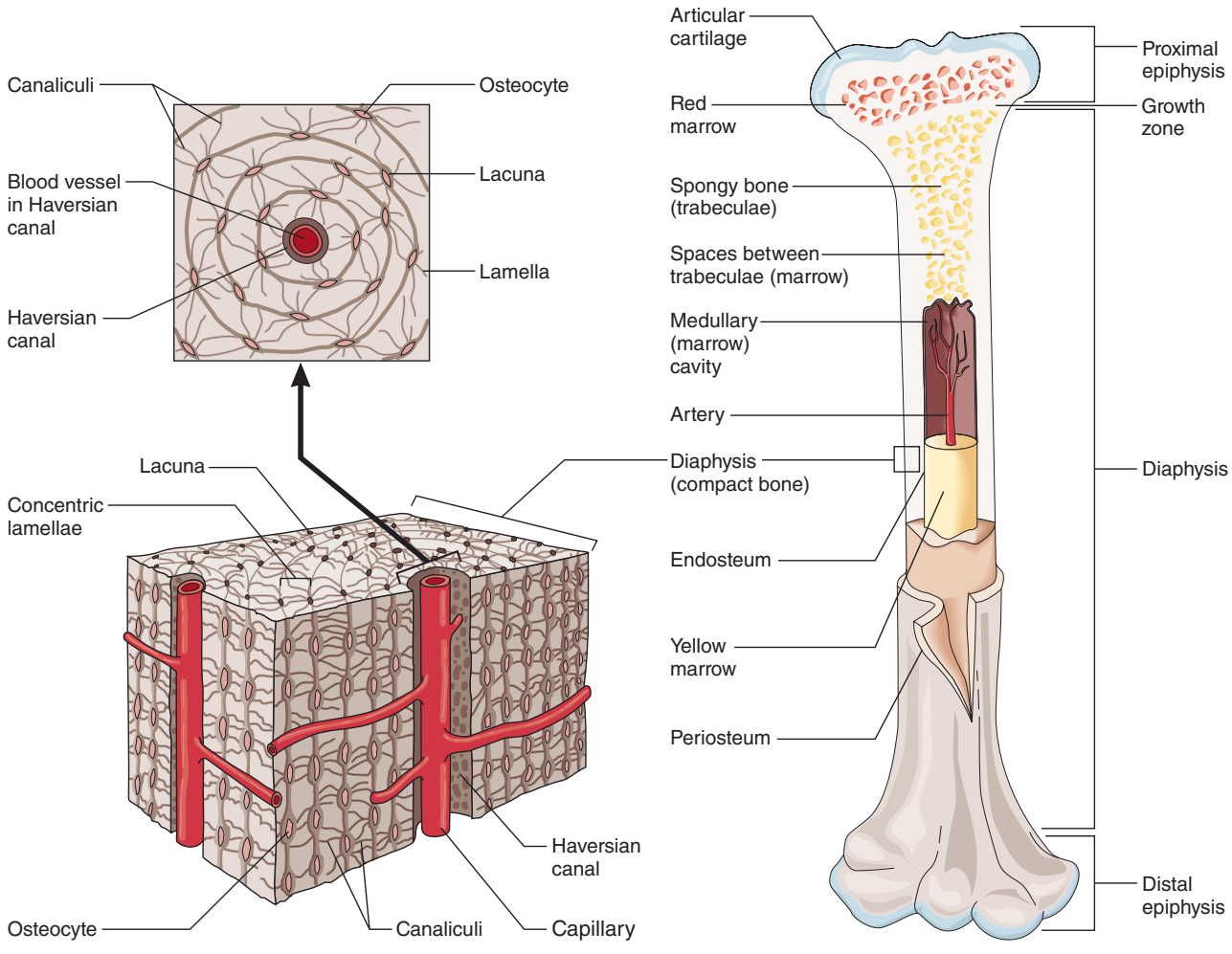

Figure 1–4. Microscopic structure of bone, revealing periosteum, haversian canals, and spongy bone trabeculae. *Source:* From Seikel/Drumright/King. *Anatomy & Physiology for Speech, Language, and Hearing, 5th Ed.* ©Cengage, Inc. Reproduced by permission.

compact bone. Notice the periosteum bound to the compact bone, and the blood supply to the entire bony structure.

Bone growth and development stand as a classic example of "use it or lose it." The density of a bone and its conformation are directly related to the amount of force placed on the bone. Using muscles causes bone to strengthen and become denser in regions stressed by that activity. Males tend to have greater muscle mass than females, and the bones of males often have more readily identifiable landmarks.

Joints

The union of bones with other bones, or cartilage with other cartilage, is achieved by means of **joints** (Figure 1–5). Joints take a variety of forms. Generally, joints are classified based on the degree of movement they permit: high mobility (**diarthrodial** joints), limited mobility (**amphiarthrodial**), or no mobility (**synarthrodial**) (Table 1–2). The joints are also classified based

diarthrodial: the class of joints of the skeletal system that permits maximum mobility

amphiarthrodial: the class of joints of the skeletal system that permit limited movement

synarthrodial: the class of joints of the skeletal system that permit no movement

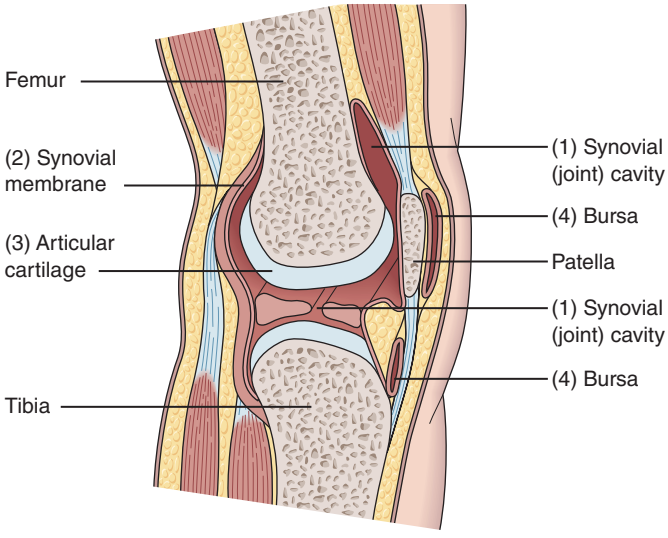

SIMPLE SYNOVIAL JOINT

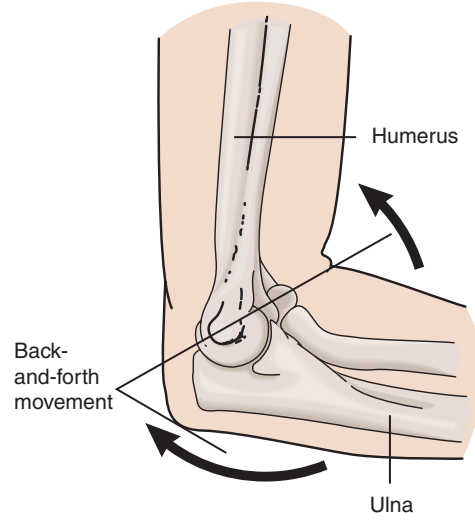

HINGE JOINT

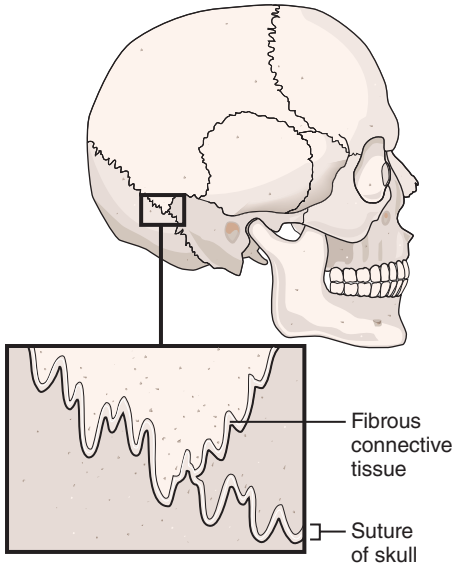

SUTURE

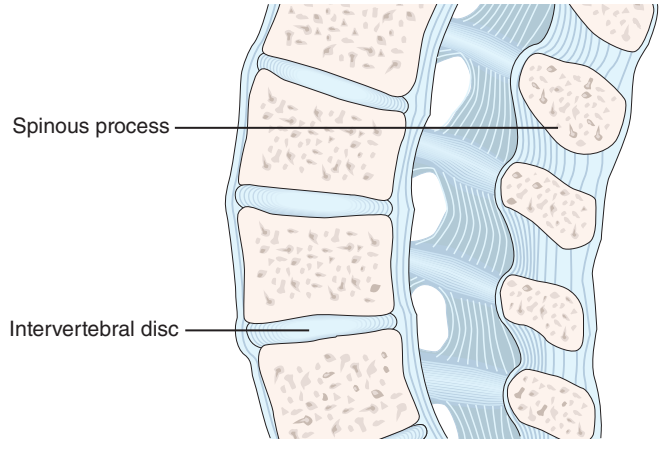

SYMPHYSIS

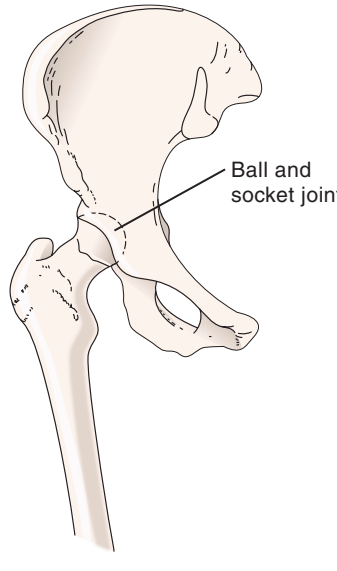

ELLIPSOID JOINT

Figure 1–5. Different types of joints. *Source:* From Seikel/Drumright/King. *Anatomy & Physiology for Speech, Language, and Hearing, 5th Ed.* ©Cengage, Inc. Reproduced by permission.

Table 1–2

Types of Joints
I. **Fibrous joints** (Immobile)
A. Syndesmosis: Banded by ligament
B. Suture: Skull bone union
C. Gomphosis: Tooth in alveolus
II. **Cartilaginous joints** (Limited movement)
A. Synchondrosis: Cartilage that ossifies through aging
B. Symphysis: Bone connected by fibrocartilage
III. **Synovial joints** (Highly mobile)
A. Plane (gliding joint; arthrodial): Shallow or flat surfaces
B. Spheroid (cotyloid): Ball and socket variant allowing wide range of movement
C. Condylar: Shallow ball-and-socket joint
D. Ellipsoid: Football-shaped ball-and-socket joint
E. Trochoid (pivot): head rotates or pivots in fossa
F. Sellar (saddle): convex and concave joint with a long axis
G. Ginglymus (hinge) One member rotates, allowing only flexion and extension

on the primary component involved in the union between bones. Synarthrodial joints are anatomically classified as **fibrous joints**, amphiarthrodial joints are **cartilaginous joints**, and diarthrodial joints are **synovial joints**, or joints containing synovial fluid within a joint space.

fibrous joints: joints that are connected by fibrous tissue

cartilaginous joints: joints in which cartilage serves to connect two bones

synovial joints: a type of diarthrodial joint that has encapsulated fluid as a cushion

syndesmosis: Gr., syndesmos, ligament; osis, condition

sutures: L., sutura, seam; immobile joints between plates of bone

gomphosis: Gr., bolting together

Fibrous Joints. There are two major types of fibrous or synarthrodial joints: syndesmoses and sutures. **Syndesmosis** joints are bound by fibrous ligaments but have little movement. **Sutures** are joints between bones of the skull that are not intended to move at all. The mating surfaces of the bones form a rough and jagged line that enhances the strength of the joint. Sutures take several forms (Figure 1–6). A **gomphosis** (peg) suture (Figure 1–6A) is one in which a peg fits into a hole. A socket (alveolus) and tooth is one such joint. A dentate (or serrate) suture (Figure 1–6B) gains its strength from the jagged (i.e., serrated) edge that mates the two bones together. This is the type of suture found, for instance, between the two parietal bones. A squamous suture (Figure 1–6C) is one in which the two mating bones actually overlap in a "keying" formation, much like current-day joining of wood sheets. A final joint, the plane joint (Figure 1–6D), is simply the direct union of two edges of bone.

Cartilaginous Joints. As the name implies, cartilaginous joints (also called amphiarthrodial joints) are those in which cartilage provides the union